Bild-Detail:

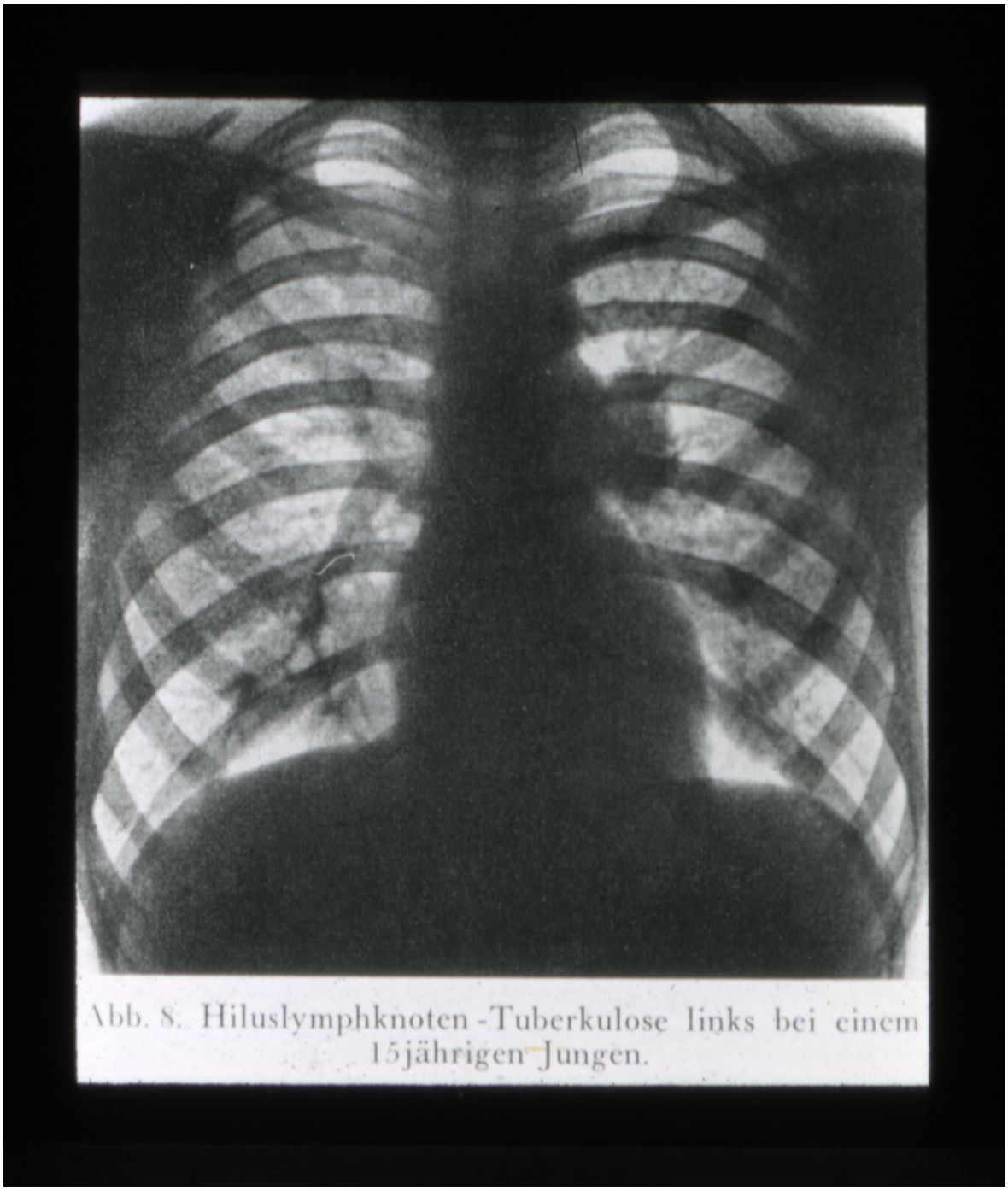
Abb. 8. Hiluslymphknoten-Tuberkulose links bei einem
15jährigen Jungen.