

Bild-Detail:

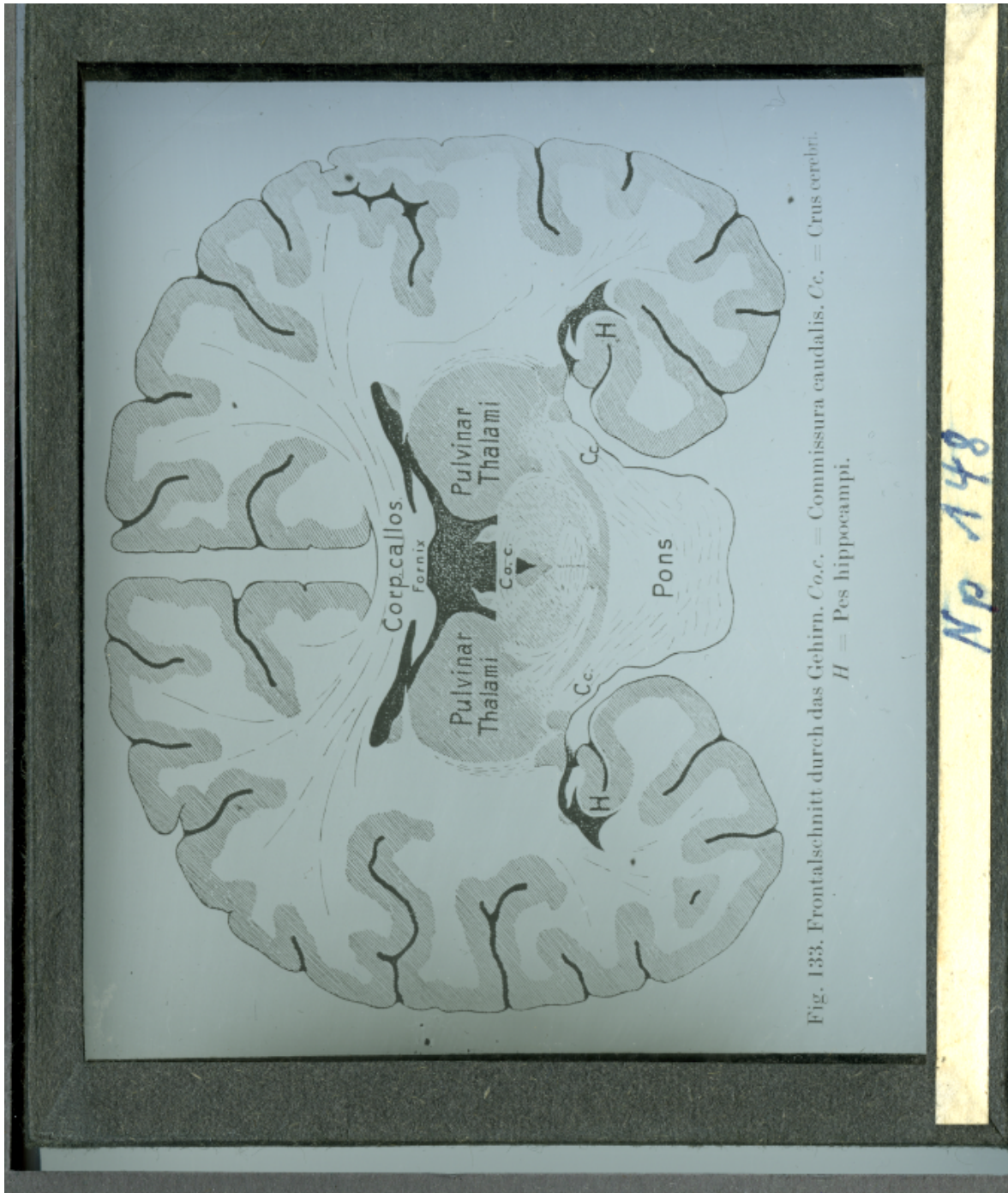


Fig. 133. Frontalschnitt durch das Gehirn. Co.c. = Commissura caudalis. Cc. = Crus cerebri.
H = Pes hippocampi.

Np 148