

Bild-Detail:

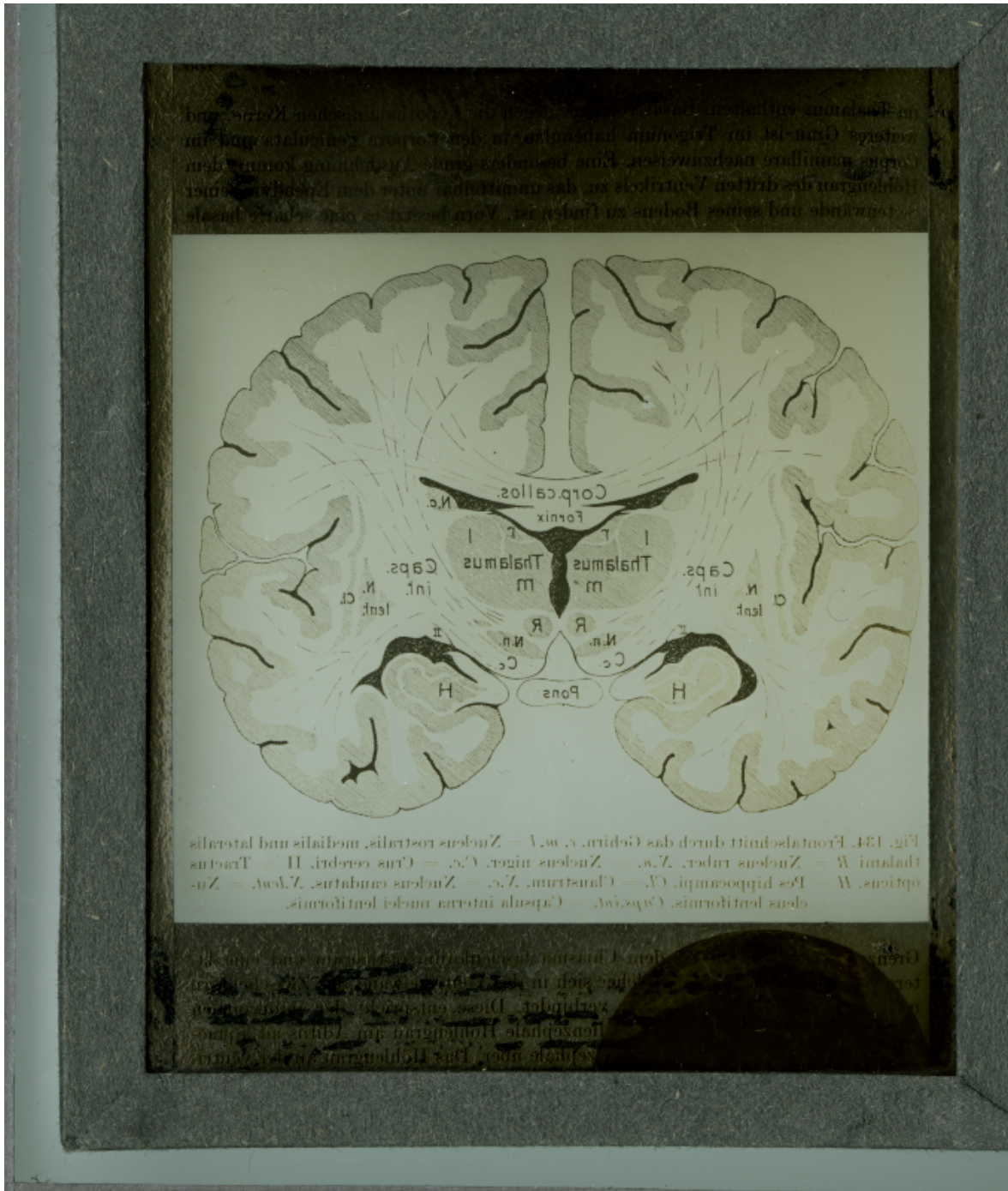


Fig. 134. Frontalschnitt durch das Gehirn. c. w. v. = Nucleus rostralis, medialis und lateralis thalami W = Nucleus tuberc. V. w. = Nucleus nigri. C. c. = Corpus cerebri. H = Thalamus opticus. W = Pars hippocampi. C. c. = Claustrum. V. c. = Nucleus caudatus. V. l. w. = Nucleus lentiformis. C. w. = Capsula interna nuclei lentiformis.