

## Bild-Detail:

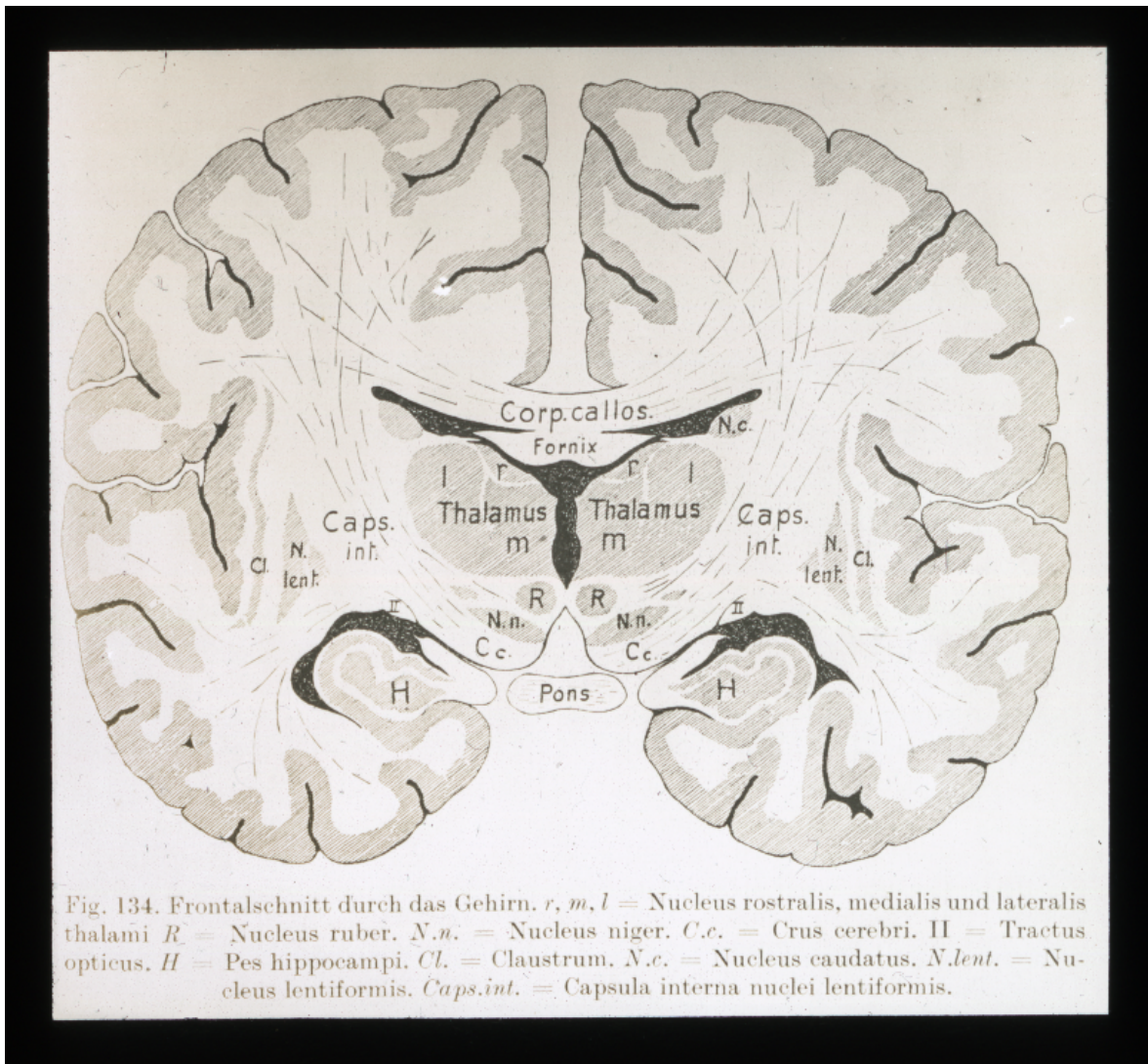


Fig. 134. Frontalschnitt durch das Gehirn. *r, m, l* = Nucleus rostralis, medialis und lateralis thalami *R* = Nucleus ruber. *N.n.* = Nucleus niger. *C.c.* = Crus cerebri. *II* = Tractus opticus. *H* = Pes hippocampi. *Cl.* = Claustrum. *N.c.* = Nucleus caudatus. *N.lent.* = Nucleus lentiformis. *Caps.int.* = Capsula interna nuclei lentiformis.