

Bild-Detail:

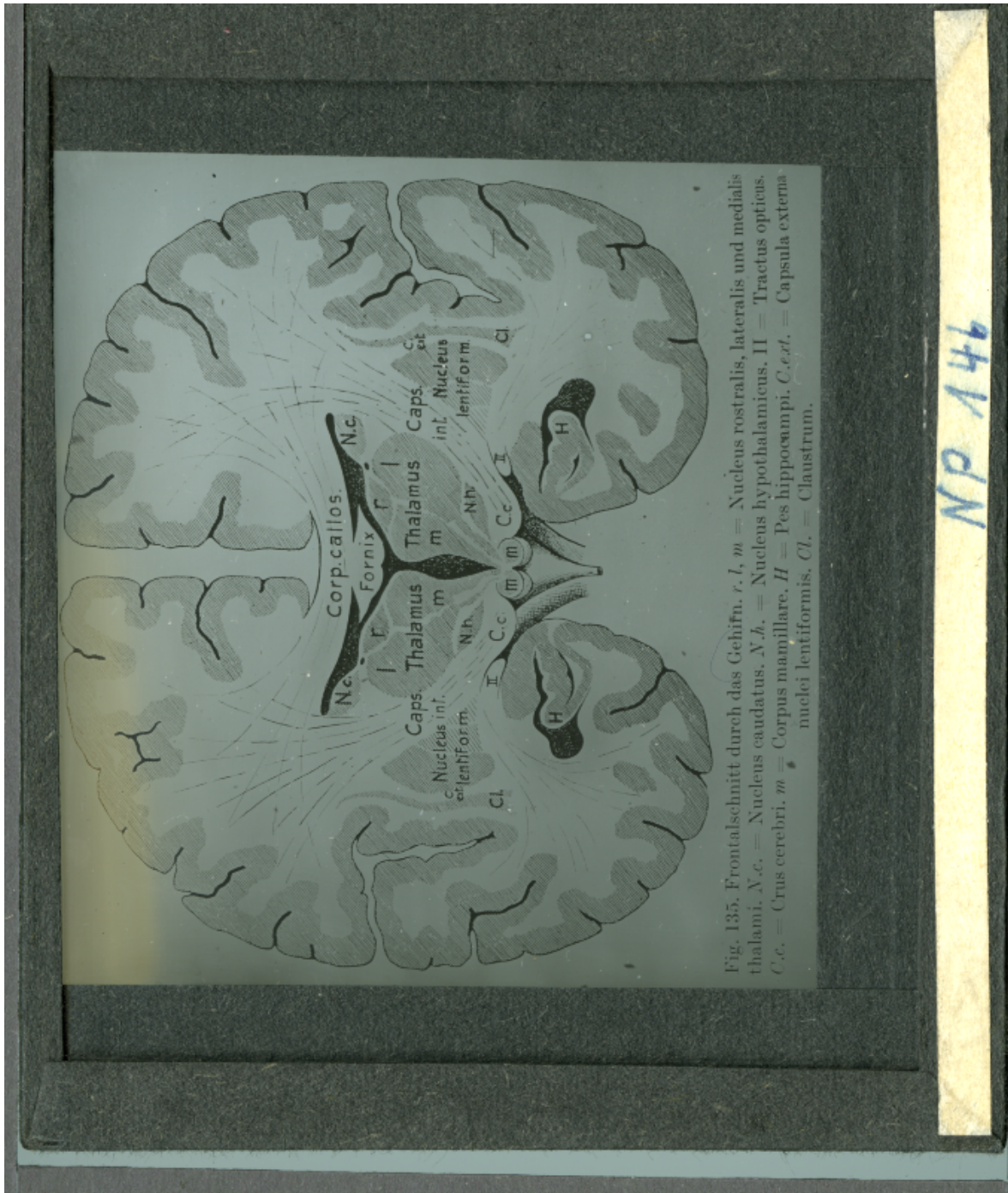


Fig. 135. Frontalschnitt durch das Gehirn. *r. l.*, *m.* = Nucleus rostralis, lateralis und medialis thalami. *N. c.* = Nucleus caudatus. *N. h.* = Nucleus hypothalamicus. *II* = Tractus opticus. *C. c.* = Crus cerebri. *m.* = Corpus mamillare. *H* = Pes hippocampi. *C. ext.* = Capsula externa nuclei lentiformis. *Cl.* = Claustrum.

NP 146