

Bild-Detail:

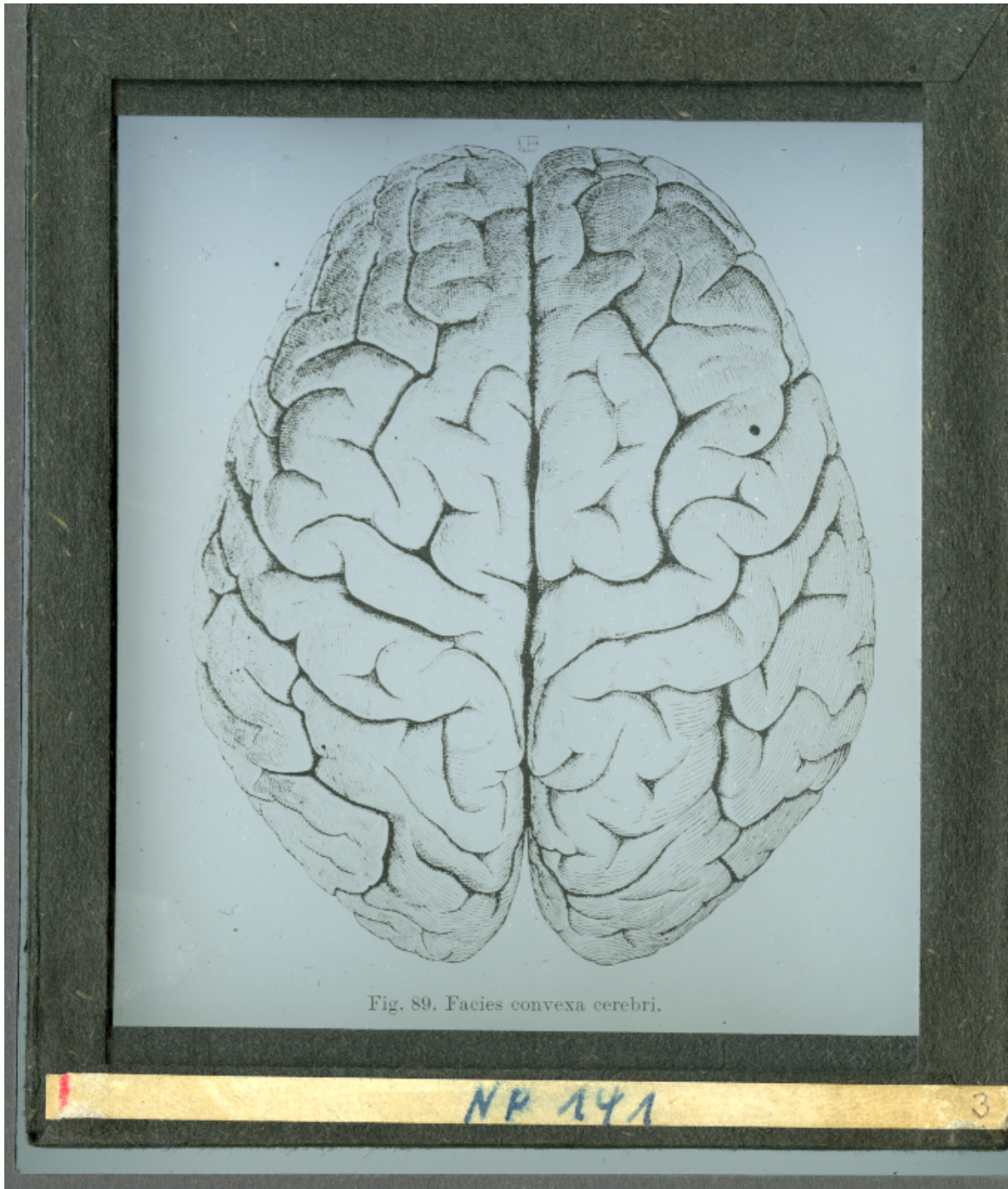


Fig. 89. Facies convexa cerebri.