Bild-Detail:

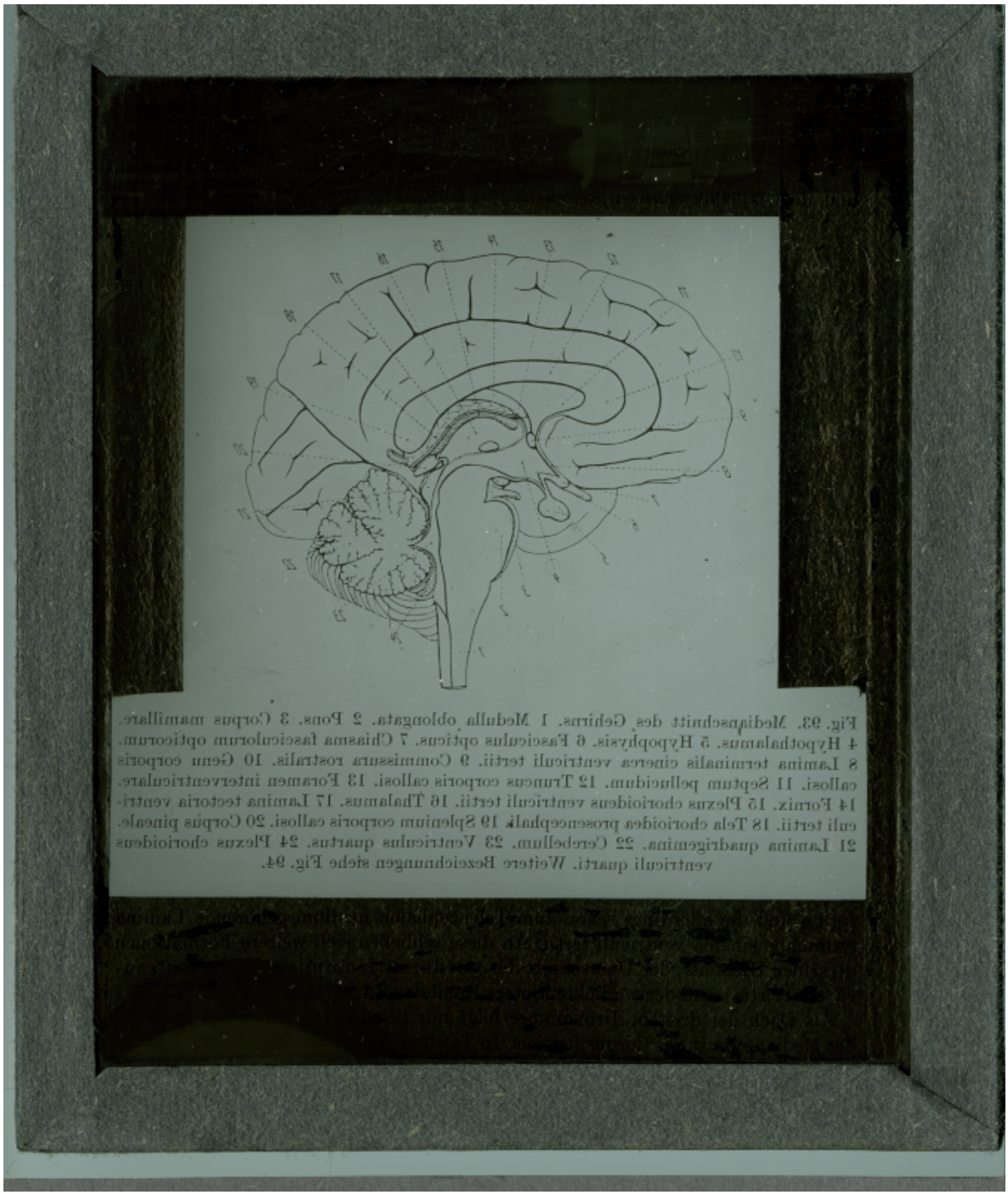
Fig. 93. Medianschnitt des Gehirns. 1 Medulla oblongata. 2 Pons. 3 Corpus mamillare.
4 Hypothalamus. 5 Hypophysis. 6 Fasciculus opticus. 7 Chiasma fasciculorum opticorum.
8 Lamina terminalis cinerea ventriculi tertii. 9 Commissura rostralis. 10 Genu corporis
callosi. 11 Septum pellucidum. 12 Truncus corporis callosi. 13 Foramen interventriculare.
14 Fornix. 15 Plexus chorioideus ventriculi tertii. 16 Thalamus. 17 Lamina tectoria ventri-
culi tertii. 18 Tela chorioidea proencephali. 19 Splenium corporis callosi. 20 Corpus pineale.
21 Lamina quadrigemina. 22 Cerebellum. 23 Ventriculus quartus. 24 Plexus chorioideus
ventriculi quarti. Weitere Bezeichnungen siehe Fig. 94.